

ONLINE FIRST

Safety, Efficacy, and Utility of Platelet-Rich Fibrin Matrix in Facial Plastic Surgery

Anthony P. Sclafani, MD

Objective: To evaluate the clinical safety and efficacy of the use of autologous platelet-rich fibrin matrix (PRFM) in facial plastic surgery.

Methods: Medical charts of the last 50 patients with at least 3 months of follow-up who were treated by the author with PRFM for aesthetic purposes were reviewed for patient satisfaction, objective clinical results, and adverse events.

Results: The study cohort of patients was followed up for a mean (SD) of 9.9 (8.0) months (range, 3-30 months). Most patients were treated for deep nasolabial folds, while the volume-depleted midface region, superficial rhytids, and acne scars were other commonly treated areas. The patients underwent an average of 1.6 treatments (range,

1-5 treatments). No patients reported any swelling lasting longer than 5 days, and most noted only minimal bruising lasting for 1 to 3 days. Most patients were satisfied with the results of their treatments, although 1 patient felt that there was limited or no improvement after 2 treatments.

Conclusions: Autologous PRFM treatment is a well-tolerated, excellent choice for use in the face. Further studies on the precise mechanism of action of PRFM are ongoing.

Arch Facial Plast Surg.

Published online February 21, 2011.

doi:10.1001/archfacial.2011.3

GROWTH FACTORS (GFs) have long represented an area of interest for surgeons attempting to modify and enhance the wound-healing process. However, a single GF application has had infrequent clinical success.^{1,2} Autologous GFs, derived from platelets, are the primary agents of action in the platelet-rich plasma (PRP) that is used currently. However, studies in facial plastic surgery have been equivocal in demonstrating clinical benefit with PRP.³⁻⁵ Also, PRP systems generally require large volumes of blood yet produce small volumes of PRP. More importantly, most PRP systems rely on animal-derived thrombin to initiate platelet degranulation, and no system has been shown to produce sustained GF release.

This "1-time" GF release that is associated with PRP use may explain the transient effect of PRP on wound healing noted by Sclafani et al,⁶ who found an increase in endothelial cells and fibroblasts 7 days after creating an experimental wound; however, this enhancement was lost by day 14. Other

investigators who were studying epidermal GF noted that the effect of exogenous epidermal GF was transient and that sustained application of epidermal GF enhanced wound repair.⁷

Platelet-rich fibrin matrix (PRFM) (Selphyl; Aesthetic Factors, Wayne, New Jersey) is distinct from PRP and can be produced with as little as 9 mL of peripheral blood. It is collected in a vacuum-sealed collection tube with a thixotropic separator gel, and the tube is centrifuged for 6 minutes at 1100 rpm. This process separates the red and white blood cells from the plasma and platelets, which are then transferred in a closed system to a second tube containing calcium chloride; it is this small amount of calcium that initiates the fibrinogen cleavage and the fibrin polymerization. The resultant mixture can be easily injected through a 30-gauge needle for approximately 10 to 12 minutes, after which the polymerization of the fibrin produces a solid fibrin clot.

Platelet-rich fibrin matrix does not produce the very high platelet concentrations that are seen in PRP. Rather, it more closely replicates the wound response. It

Author Affiliations: Division of Facial Plastic and Reconstructive Surgery, The New York Eye and Ear Infirmary, New York, New York; and Department of Otolaryngology, New York Medical College, Valhalla, New York.

Table. The Average Volumes Injected, by Area

Area Injected/Treated	Volume, Mean (SD), mL
Superficial rhytids	
Forehead	0.30 (0.10)
Glabella	0.38 (0.17)
Crow's feet	0.48 (0.25)
Tear trough	0.65 (0.43)
Orbital hollow	1.00 (0.38)
Nasolabial fold	1.67 (0.78)
Marionette fold	0.80 (0.31)
Midfacial volume	
Cheek	1.59 (0.71)
Malar eminence	1.08 (0.11)
Upper lip	2.50 (0.17)
Lower lip	1.50 (0.10)
Mental crease	0.51 (0.30)
Prejowl sulcus	0.50 (0.33)
Acne scars (with subcision)	
Forehead	0.47 (0.25)
Temple	0.86 (0.35)
Cheek	2.25 ^a
Surgery, lateral osteotomy site	1.50 ^a
Cheek or chin implant	2.00 ^a
Rhytidectomy	2.00 ^a

^aAll injection volumes were the same for each area; therefore, there was no variance.

includes the formation of a 3-dimensional cross-linked fibrin matrix, which is essential to the platelet plug, as it serves as a binding site for both platelets and GFs. This scaffolding helps localize the GFs, essentially increasing the local concentration at the desired location to guide tissue regeneration.

I previously described my early clinical experience with PRFM⁸ and reported the results of a clinical trial of PRFM for the improvement of deep nasolabial folds.⁹ In the latter study, patients were treated with a single (intra-dermal and/or subdermal) injection of PRFM for moderately severe nasolabial folds. Clinically significant improvement in the nasolabial folds was noted as early as 2 weeks after treatment, with slight improvement (no loss of correction) over the following 10 weeks of the trial.

Since 2008, I have used PRFM to treat deep nasolabial folds and superficial rhytids as well as for facial volumization and depressed or acne scars (in combination with subcision), mixed with fat (as described by others^{10,11}), and to accelerate wound healing in face-lifts, facial implants, and lateral osteotomies in rhinoplasties. This article presents a review of 50 cases that were treated with PRFM in my practice.

METHODS

Office medical charts were reviewed to identify the last 50 patients who had been treated with PRFM with a minimum of 3 months of follow-up. They were reviewed for patient demographics as well as for the following PRFM treatment parameters: specific intended goals of treatment, number of treatments, areas treated, volumes injected, posttreatment sequelae, and length of follow-up.

PREPARATION OF PRFM

Autologous PRFM was prepared with the following system: Briefly, 9 mL of peripheral blood was collected in a specialized vacuum-sealed collection tube containing an anticoagulant (sodium citrate) and a separator gel. Next, the tube was centrifuged for 6 minutes at 1100 rpm, separating the cellular components below the gel and plasma and platelets above the gel. Platelets and plasma were then transferred to a second tube containing calcium chloride, and the PRFM was injected using a 27- or 30-gauge needle into the dermis, subdermis, or preperiosteal plane as needed.

PRFM APPLICATION

Fine rhytids are injected intradermally, while deeper folds and areas of volume deficiency are injected at the dermal-subdermal border. Some areas requiring significant volume augmentation may also be injected into deep fat (midface) or preperiosteally (suborbital hollows). Depressed or acne scars are treated with a combination of subcision followed immediately by subdermal injection of PRFM. Surgical applications of PRFM include rhinoplasty, in which PRFM is injected along the lateral osteotomy site; rhytidectomy, in which PRFM is placed in a thin layer over the flap bed before closure; and autologous fat transfer, in which PRFM is mixed with fat in a 1:2 ratio^{10,11} just before fat injection.

RESULTS

The study included 44 women and 6 men, with a mean (SD) age of 51.3 (12.6) years (age range, 23.5-72.5 years). The patients were treated an average of 1.8 times (range, 1-5 treatments). Most patients were Fitzpatrick skin type II or III, but 4 patients were skin type IV. The indications for treatment are listed below.

Indication	No. of Patients
Nasolabial folds	30
Facial volumization	11
Superficial rhytids	10
Acne scars	6
Rhinoplasty	4
Facial implant	2
Autologous fat transfer	2
Rhytidectomy	2
Depressed scar	1

The average volumes injected, by area, are listed in the **Table**. The mean (SD) duration of follow-up was 9.9 (8.0) months (range, 3-30 months).

Patients generally noted that the correction seen immediately after treatment subsided partially over the first 24 to 72 hours afterward. Most patients noted only mild bruising, which was easily covered with cosmetics, for the first 1 to 3 days, although a few patients (especially those treated in the periorbital area) experienced ecchymosis lasting up to 14 days. Most patients perceived noticeable improvement in the treated areas by 5 to 7 days after treatment, and almost all (approximately 90%) noticed continued improvement until 2 to 4 weeks after treatment. Five patients felt that the changes after their first treatment were minimal and were re-treated; of these, 4 did note improvement after the second treatment. No patients

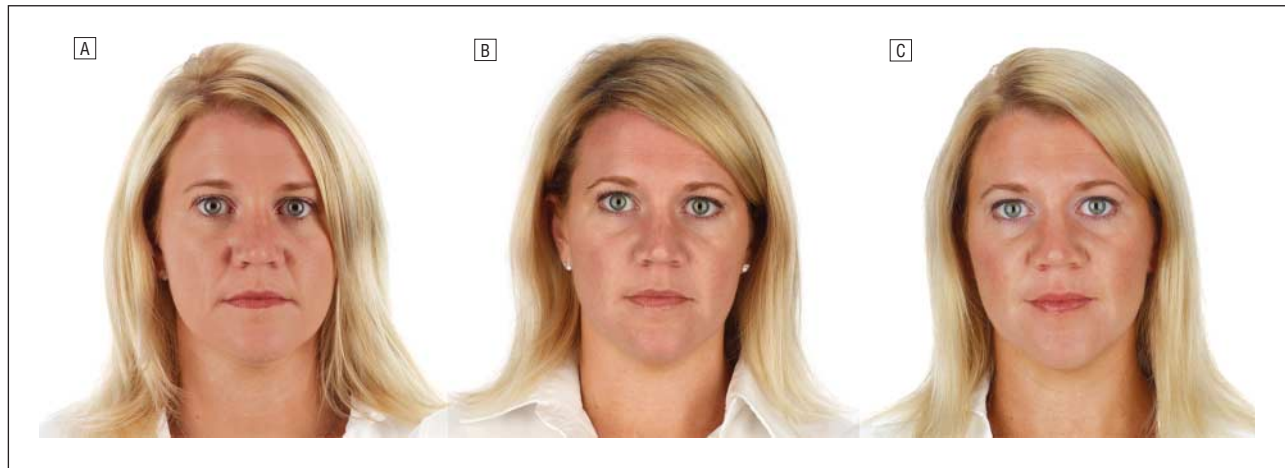


Figure 1. Photographs taken before (A) and 3 (B) and 12 (C) months after a single treatment with intradermal and subdermal injection of platelet-rich fibrin matrix for improvement of the nasolabial folds. Generally, improvement is noted within 2 to 3 weeks. Comparison of the 3- and 12-month views demonstrates stability and durability of correction over time.

noted any nodules, irregularity, excessive correction, or restriction of movement.

COMMENT

Autologous tissue would be the ideal material choice for soft-tissue augmentation in the face if it could be provided in a simple process with good predictability. Need for tissue harvesting, access incisions, postoperative recovery, and often unpredictable graft survival and longevity have encouraged physicians to consider other available minimally invasive techniques and materials. These materials, however, may be resorbed, infected, or associated with a chronic granulomatous response. Early attempts to use the patient's own collagen to promote soft-tissue augmentation showed limited persistence.¹² Injection of cultured autologous fibroblasts was expensive and time consuming and provided equivocal results.¹³

Dermal stimulation with exogenous microparticles (eg, poly-L-lactic acid) has been shown to effectively thicken the dermis. However, the results require multiple treatments, and care must be taken to avoid nodularity and granulomas. Moreover, this technique requires implantation of a foreign body to act as the stimulus for collagen deposition.¹⁴

Ideally, the body's natural capacity to generate collagen would be used to create additional bulk. In a study examining the effects of PRP, my colleagues and I noted an early increase in endothelial cells and fibroblasts in a wound, which did not persist after 7 days.⁶ This early effect on fibroblasts and endothelial cells, however, spurred our interest in harnessing the body's natural mechanisms for wound repair and collagen production for use in soft-tissue augmentation.

Platelet-rich fibrin matrix (Selphyl) has been available in the United States for several years and has been used clinically in orthopedic surgical and wound-healing applications. In a study of chronic, nonhealing venous leg ulcers, O'Connell et al¹⁵ were able to induce closure in 66.7% of wounds within 16 weeks with topi-

cal application of PRFM. In facial plastic surgery, a clinically significant reduction of Wrinkle Assessment Scale scores was noted after a single intradermal/subdermal injection of PRFM into moderate to deep nasolabial folds. The improvement was noted as early as 2 weeks after treatment and persisted throughout the 12-week duration of the study.

I believe that autologous PRFM produces sustained tissue effects because it more closely mimics the body's natural wound-healing response. As opposed to PRP, PRFM does not rely on extremely high concentrations of platelets and a massive, 1-time release of GFs but rather on providing a more natural, sustained wound response. It concentrates platelets but not to the extreme degree seen in PRP. Instead, platelets are delivered to the tissue accompanied by an actively polymerizing 3-dimensional fibrin mesh. This mesh serves to localize tissue activity because both platelets and their GFs bind to it, as in the natural wound. Moreover, platelets in PRFM *in vitro* have been shown to continue to synthesize and release bioactive GFs over the first 7 days.¹⁶ It is this natural, sustained GF release that I believe is critical to the development of the sustained tissue effects. By localizing platelets and GFs and fostering a physiologic tissue response in the treated area, PRFM produces guided tissue regeneration. According to the preliminary results from an ongoing histologic study of skin treated with PRFM, new collagen has been identified as early as 7 days after treatment, and maturing collagen fibers are still evident at 10 weeks.

Platelet-rich fibrin matrix can be used to correct fine rhytids and deeper folds as well as for facial volumization (**Figure 1**). It can also be combined with subcision to improve the appearance of rolling acne scars. Two and a half years of clinical experience using PRFM has shown it to be safe and effective, producing relatively early clinical improvements with prolonged effect. No patients have seen the total loss of the original correction, and only a few have noticed any significant loss of effect; it is unclear whether this loss of effect represents resorption of new collagen or is simply

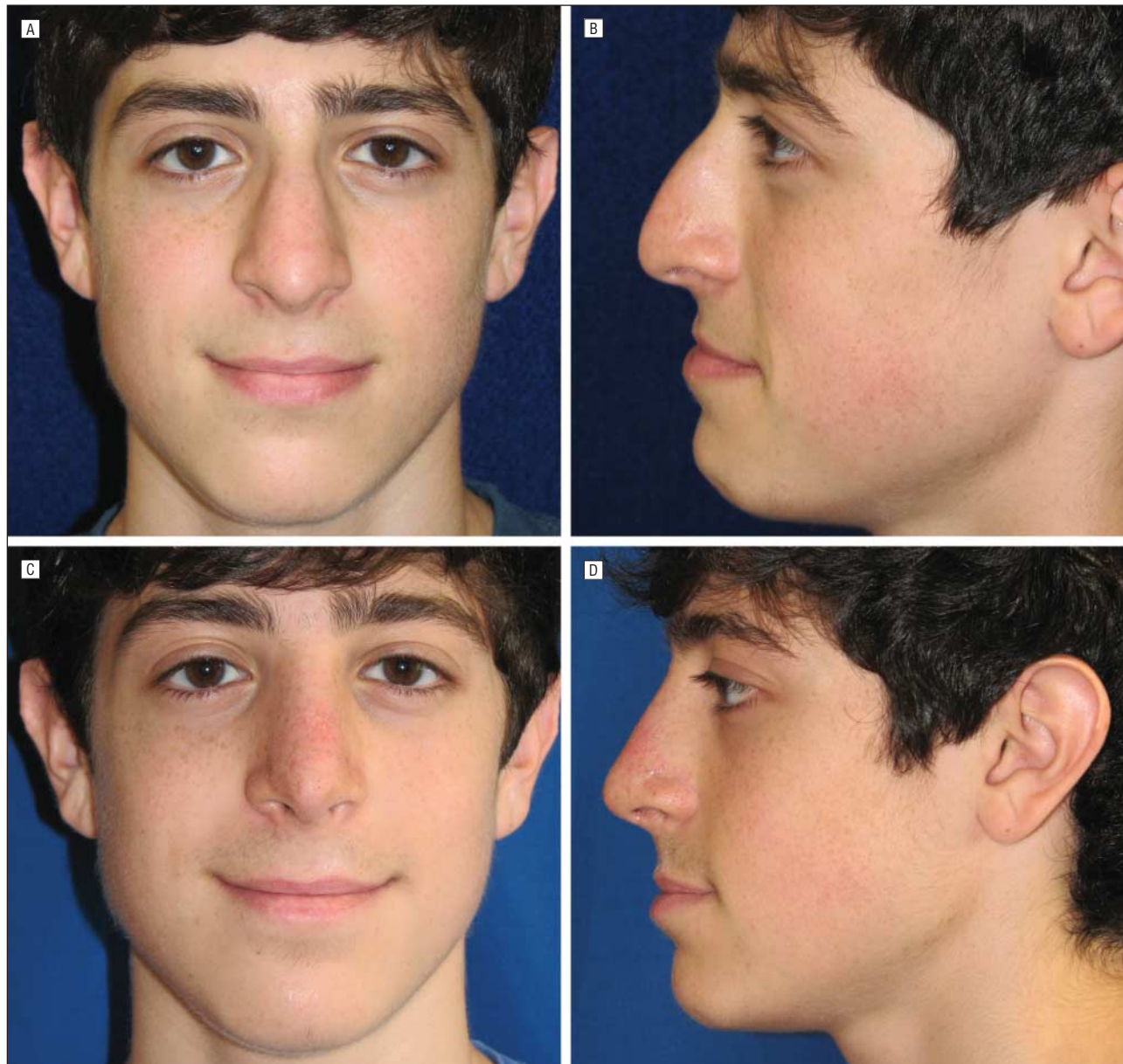


Figure 2. Photographs taken before (A and B) and after (C and D) treatment with platelet-rich fibrin matrix. A and B, Preoperative views of a patient undergoing external rhinoplasty with tip contouring and grafting in addition to dorsal reduction and bilateral medial, intermediate, and lateral osteotomies. Platelet-rich fibrin matrix is injected along the intermediate and lateral osteotomy lines immediately before the dorsal cast is applied. C and D, Photographs taken immediately after removal of the cast and sutures on postoperative day 6 show no ecchymosis and limited edema.

the result of continued aging in these patients. I have also used PRFM adjunctively during rhytidectomy, rhinoplasty (**Figure 2**), and autologous fat transfer to promote wound healing, to limit ecchymosis and edema, and to accelerate angiogenesis and revascularization, respectively. No patient has developed any irregularity, nodularity, or excessive fibrosis.

It has also become clear that initial overcorrection is desirable, as some of the injected volume is related to the plasma volume, which is rapidly resorbed over a 3- to 12-hour period. Indeed, initial undercorrection may explain why some patients responded clinically to a second injection after failing to show clinically significant improvement after the initial treatment. It should be noted, however, that 1 patient failed to show clinically relevant

improvement after 2 injections, and patients should be advised that unknown factors (possibly related to their skin or platelet function) may prevent generation of an adequate response. However, sustained clinical results have been seen over the long term, and PRFM represents the only natural-based method of autologous tissue regeneration.

Accepted for Publication: December 10, 2010.

Published Online: February 21, 2011. doi:10.1001/archfacial.2011.3

Correspondence: Anthony P. Scclafani, MD, Division of Facial Plastic and Reconstructive Surgery, The New York Eye and Ear Infirmary, 310 E 14th St, New York, NY 10003 (asclafani@nyee.edu).

Author Contributions: Dr Sclafani had full access to all the data in the study and takes responsibility for the integrity of the data and the accuracy of the data analysis. **Financial Disclosure:** Dr Sclafani is a consultant for, and has received research support from, Aesthetic Factors. **Previous Presentation:** This study was presented in part at the Annual Meeting of the American Academy of Facial Plastic and Reconstructive Surgery; September 24, 2010; Boston, Massachusetts.

REFERENCES

1. Papanas N, Maltezos E. Benefit-risk assessment of becaplermin in the treatment of diabetic foot ulcers. *Drug Saf.* 2010;33(6):455-461.
2. Beaven AW, Shea TC. The effect of palifermin on chemotherapy and radiation therapy-induced mucositis: a review of the current literature. *Support Cancer Ther.* 2007;4(4):188-197.
3. Hom DB. New developments in wound healing relevant to facial plastic surgery. *Arch Facial Plast Surg.* 2008;10(6):402-406.
4. Powell DM, Chang E, Farrior EH. Recovery from deep-plane rhytidectomy following unilateral wound treatment with autologous platelet gel: a pilot study. *Arch Facial Plast Surg.* 2001;3(4):245-250.
5. Danielsen P, Jørgensen B, Karlsmark T, Jørgensen LN, Agren MS. Effect of topical autologous platelet-rich fibrin versus no intervention on epithelialization of donor sites and meshed split-thickness skin autografts: a randomized clinical trial. *Plast Reconstr Surg.* 2008;122(5):1431-1440.
6. Sclafani AP, Romo T III, Ukrainsky G, et al. Modulation of wound response and soft tissue ingrowth in synthetic and allogeneic implants with platelet concentrate. *Arch Facial Plast Surg.* 2005;7(3):163-169.
7. Buckley A, Davidson JM, Kamerath CD, Wolt TB, Woodward SC. Sustained release of epidermal growth factor accelerates wound repair. *Proc Natl Acad Sci U S A.* 1985;82(21):7340-7344.
8. Sclafani AP. Applications of platelet-rich fibrin matrix in facial plastic surgery. *Facial Plast Surg.* 2009;25(4):270-276.
9. Sclafani AP. Platelet-rich fibrin matrix for improvement of deep nasolabial folds. *J Cosmet Dermatol.* 2010;9(1):66-71.
10. Azzena B, Mazzoleni F, Abatangelo G, Zavan B, Vindigni V. Autologous platelet-rich plasma as an adipocyte in vivo delivery system: case report. *Aesthetic Plast Surg.* 2008;32(1):155-161.
11. Cervelli V, Gentile P. Use of platelet gel in Romberg syndrome. *Plast Reconstr Surg.* 2009;123(1):22e-23e.
12. Sclafani AP, Romo T III, Parker A, McCormick SA, Cocker R, Jacono A. Autologous collagen dispersion (Autologen) as a dermal filler: clinical observations and histologic findings. *Arch Facial Plast Surg.* 2000;2:48-52.
13. Watson D, Keller GS, Lacombe V, Fodor PB, Rawnsley J, Lask GP. Autologous fibroblasts for treatment of facial rhytids and dermal depressions. A pilot study. *Arch Facial Plast Surg.* 1999;1(3):165-170.
14. Mest DR, Humble G. Safety and efficacy of poly-L-lactic acid injections in persons with HIV-associated lipoatrophy: the US experience. *Dermatol Surg.* 2006;32(11):1336-1345.
15. O'Connell SM, Impeduglia T, Hessler K, Wang XJ, Carroll RJ, Dardik H. Autologous platelet-rich fibrin matrix as cell therapy in the healing of chronic lower-extremity ulcers. *Wound Repair Regen.* 2008;16(6):749-756.
16. Carroll RJ, Arnoczky SP, Graham S, O'Connell SM. *Characterization of Autologous Growth Factors in Cascade Platelet-Rich Fibrin Matrix (PRFM)*. Edison, NJ: Musculoskeletal Transplant Foundation; 2005.